

Subcutaneous fat necrosis in a 2 day old neonate

Rosa Beatriz S Diaz,¹ Bai Shariffah B Pandita Reyes,¹ Lea Fatima B Hingpit,¹
Lalaine R Visitacion¹

¹Department of Dermatology, Southern Philippines Medical Center, JP Laurel Ave, Davao City, Philippines

Correspondence

Rosa Beatriz S Diaz,
rosabeatrizsantander.diaz24@gmail.com

Received

13 December 2022

Accepted

23 June 2023

Published online

29 June 2023

Cite as

Diaz RBS, Pandita-Reyes BSB, Hingpit LFB, Visitacion LR. Subcutaneous fat necrosis in a 2-day old neonate. *SPMC J Health Care Serv.* 2023 9(1):8. <http://n2t.net/ark:/76951/jhcs249chq>

Copyright

© 2023 RBS Diaz, et al.

Subcutaneous fat necrosis of the newborn (SCFN) is a rare disorder characterized by the development of indurated nodules or plaques on the back, buttocks, and limbs of infants, typically occurring within the first few weeks of life.¹⁻³ SCFN commonly affects full-term newborns with normal weight.⁴ The etiology of SCFN remains unknown, and there is currently no known familial association.¹⁻³⁻⁵ A retrospective study conducted at a tertiary referral hospital located in Canada identified 30 newborns diagnosed with SCFN over a span of 20 years, but the global incidence of the condition remains to be unknown.⁶ However, SCFN has been associated with several perinatal risk factors, including meconium aspiration, neonatal sepsis, gestational diabetes, pre-eclampsia, maternal toxicity, and obstetric trauma.¹⁻⁴⁻⁷ Neonatal distress interferes with blood flow to adipose tissues, creating a hypoxic and hypothermic environment that progresses to inflammation and necrosis.⁷

Prompt diagnosis of SCFN is essential due to the potential occurrence of serious extracutaneous abnormalities, such as thrombocytopenia, hypoglycemia, hypertriglyceridemia, and hypercalcemia.¹⁻⁸ Hypercalcemia had been observed in 63% of patients with SCFN, and some of them developed nephrocalcinosis and calcinosis of the gallbladder. While normocalcemia among SCFN patients signifies a better overall prognosis, monitoring is recommended between one and six months after the development of subcutaneous nodules.⁶ A definitive diagnosis of SCFN requires consideration of both the clinical presentation and a skin biopsy. Ultrasonography examination, combined with Doppler blood flow analysis, has also been shown to be effective and can serve as an alternative to a skin biopsy. Treatment primarily focuses on providing supportive care since cutaneous lesions typically resolve spontaneously in most cases.¹⁹

A 17-day-old male neonate was referred to our department due to erythematous and violaceous cutaneous lesions, which began during his first 48 hours of life. The patient was born full-term and large for gestational age, weighing 3.92 kilograms, through normal spontaneous delivery. The APGAR scores were 1, 5, and 8 at 1, 5, and 10 minutes, respectively. Immediately after birth, the patient had cyanosis, decreased pulses, and absence of breathing, suggestive of both meconium aspiration syndrome and neonatal sepsis. The patient underwent resuscitation, requiring intubation, and was initiated on a course of broad-spectrum antibiotics during the first 24 hours of life, followed by antifungals on the third day of life. Several tests and procedures were conducted, including an echocardiogram, ruling out any congenital heart defects. Chest radiograph findings revealed bilateral pneumonia. On the second day of life, a 3-centimeter erythematous patch appeared on the patient's posterior trunk. At this time, the patient's blood picture showed thrombocytopenia, so platelet concentrate was transfused on the 3rd, 6th, and 7th day of life.

The patient was extubated on the 9th day of life and was shifted from mechanical ventilation to oxygen support via nasal cannula until the 12th day of life. The cutaneous lesions gradually increased in size and number and progressed into multiple erythematous to violaceous indurated patches, nodules, and plaques affecting most of the posterior trunk. On the 12th day of life, the lesions extended to the sacral area. Blood culture results, which came out on the 11th and 20th day of life, revealed the growth of *Bacillus* species and *Staphylococcus epidermidis*. Initially, an infectious cause of the lesions on the posterior trunk was suspected, but the lesions persisted despite two weeks of intravenous antibiotic treatment. These developments prompted a referral to our department for further evaluation. No symptoms related to abnormalities in the cardiovascular, genitourinary, and gastrointestinal systems were reported. There is no known history of SCFN or any similar disorder within the patient's family. The patient's mother had a non-smoking history and denied any consumption of alcohol, drugs, or medications during pregnancy. Apart from the documented COVID-19 infection upon admission, no other maternal illnesses were reported. On physical examination, the patient appeared comfortable with no signs of respiratory distress. We observed the presence of multiple indistinct indurated patches, nodules, and plaques across the patient's shoulders, the dorsal aspect of the upper forearms, the posterior trunk, and the gluteal area (Figure 1A). The rest of the physical



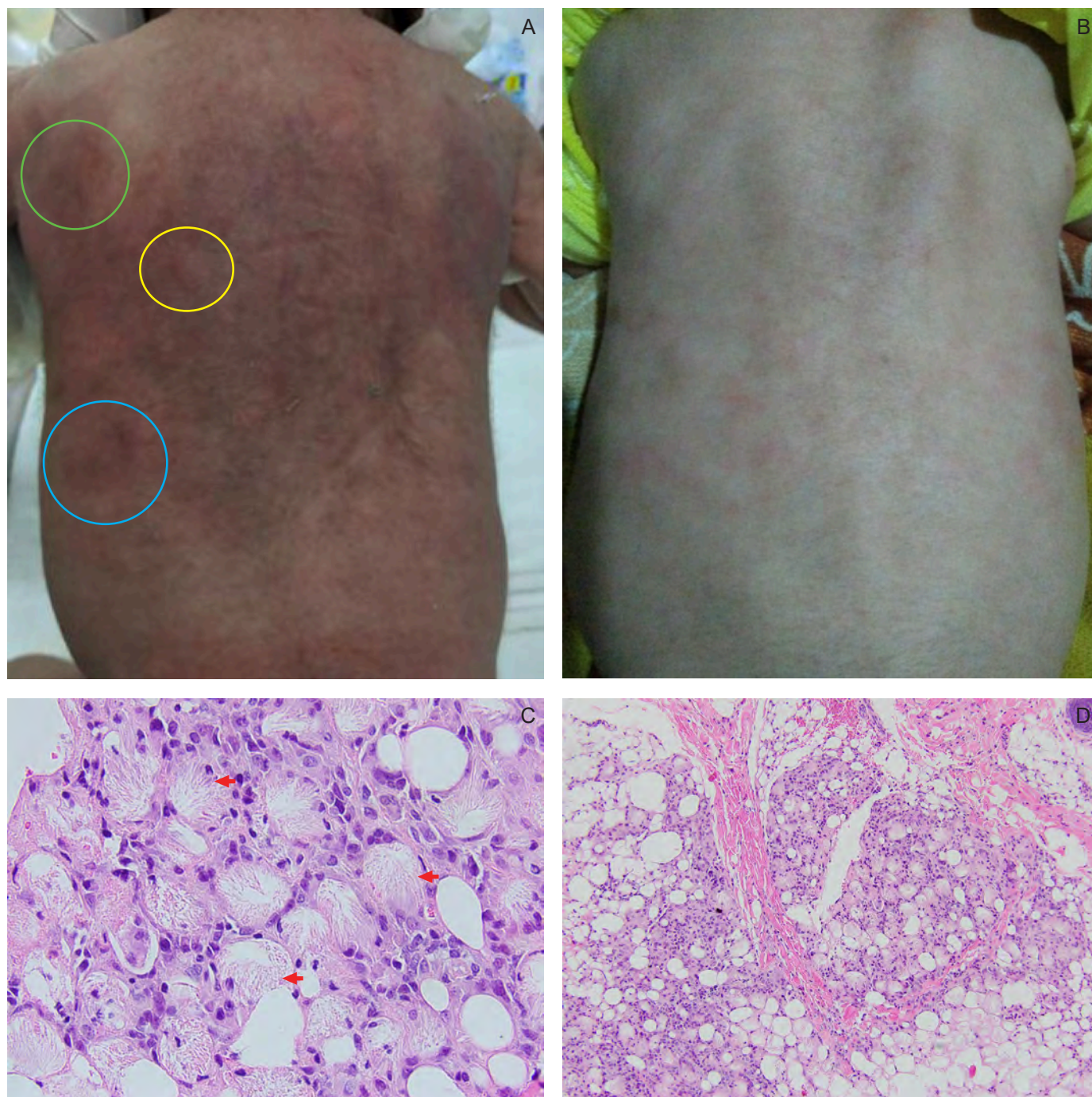


Figure 1 Multiple erythematous to violaceous patches (A: blue ring) and plaques, (A: green ring) and indurated nodules (A: yellow ring) on the patient's posterior trunk on the 17th day of life. An almost complete clearance of the patient's cutaneous lesions upon discharge on the 28th day of life (B). Lobular panniculitis with multiple eosinophilic strands and needle-shaped clefts (C: red arrows) in radial arrays within adipose lobules. Prominent lobular infiltrates composed of lymphocytes and histiocytes (D) (hematoxylin-eosin stain, C: $\times 400$ and D: $\times 100$).

examination findings were unremarkable.

At the time of our evaluation, the patient was no longer thrombocytopenic. Additional blood tests revealed hypoalbuminemia (29 g/L; normal range: 32 to 48 g/L), normocalcemia (2.79 mmol/L; normal range: 1.75 to 3.00 mmol/L), and hypertriglyceridemia (3.09 mmol/L; normal range: 1.7 mmol/L to 2.3 mmol/L). An ultrasonography of the entire abdomen showed no abnormalities. Initially, our provisional diagnosis pointed towards SCFN of the newborn. However, we deemed it necessary to rule out sclerema neonatorum, a more severe condition. Histopathologic examination plays a role in arriving at a proper diagnosis. Biopsy samples taken from both SN and SCFN show lobular panniculitis with needle-like crystals within adipocytes.¹⁰ However, unlike SN, which typically shows little to no inflammation, SCFN demonstrates the presence of inflammatory infiltrates and foreign-body giant cells upon histologic examination.⁹ We obtained a skin punch biopsy sample from the patient's posterior trunk, where the majority of cutaneous lesions were located. Histopathologic examination of the sample revealed the presence of fine eosinophilic strands and needle-shaped clefts arranged radially within the adipose lobules, accompanied by focal fat necrosis (Figure 1C and Figure 1D). These findings are consistent with SCFN.

During our evaluation of the patient, no therapeutic interventions were required. At the time of referral, the lesions on the patient were already undergoing expected resolution according to the natural course of SCFN. Throughout the patient's stay, we monitored the lesions and remained vigilant for potential complications, such as thrombocytopenia, hypoglycemia, hypertriglyceridemia, and hypercalcemia. Among these complications, only hypertriglyceridemia was observed, but no specific intervention was required at the time of evaluation. Hypertriglyceridemia in similar cases of SCFN has been known to be transient and may improve spontaneously without any sequelae.¹¹ We thoroughly explained to the patient's parents the importance of regular follow-up consultations until the age of 6 months. We emphasized the significance of identifying any potential complications, particularly the signs of hypercalcemia such as constipation, seizures, dehydration, feeding intolerance, and failure to thrive. The pediatric service continued the administration of intravenous antibiotics and antifungals, which was completed during the patient's first month of life. An almost complete resolution of the cutaneous lesions was noted upon the patient's discharge on the 28th day of life (Figure 1B).

Contributors

RBSD, BSBPR, LFBH, and LRV contributed to the diagnostic and therapeutic care of the patient in this report. All of them acquired relevant patient data, and searched for and reviewed relevant medical literature used in this report. RBSD wrote the original draft, performed the subsequent revisions. All approved the final version, and agreed to be accountable for all aspects of this report.

Patient consent

Obtained

Article source

Submitted

Peer review

External

Competing interests

None declared

Access and license

This is an Open Access article licensed under the Creative Commons Attribution-NonCommercial 4.0 International License, which allows others to share and adapt the work, provided that derivative works bear appropriate citation to this original work and are not used for commercial purposes. To view a copy of this license, visit <http://creativecommons.org/licenses/by-nc/4.0/>.

REFERENCES

1. Velasquez JH, Mendez MD. Newborn Subcutaneous Fat Necrosis. [Updated 2023 May 1]. In: StatPearls [Internet]. Treasure

Island (FL): StatPearls Publishing. 2023 Jan-. Available from: <https://www.ncbi.nlm.nih.gov/books/NBK557745/>.

2. Lorenzo C, Romana A, Matias J, Calhau P. Subcutaneous fat necrosis of the newborn - An atypical case with typical complications. Clin Case Rep. 2021 Feb 18 9(4):2069-2073.

3. Mendiratta V, Yadav A, Makhija M. Subcutaneous Fat Necrosis of the Newborn. Indian Dermatol Online J. 2020 May 10 11(3):471-472.

4. Chuang SD, Chiu HC, Chang CC. Subcutaneous fat necrosis of the newborn complicating hypothermic cardiac surgery. Br J Dermatol. 1995 May 132(5):805-10.

5. Kellar A, Tangatco JA, Weinstein M, Saunders N. Subcutaneous Fat Necrosis of the Newborn With Initial Hypocalcemia and Familial Recurrence: A Case Report. J Cutan Med Surg. 2018 Mar/Apr 22(2):223-225.

6. Del Pozzo-Magaña BR, Ho N. Subcutaneous Fat Necrosis of the Newborn: A 20-Year Retrospective Study. Pediatr Dermatol. 2016 Nov 33(6):e353-e355.

7. Lara LG, Villa AV, Rivas MM, Capella MS, Prada F, Enseñat MA. Subcutaneous Fat Necrosis of the Newborn: Report of Five Cases. Pediatr Neonatol. 2017 Feb 58(1):85-88.

8. Grass B, Weibel L, Hagmann C, Brotschi B. National Asphyxia and Cooling Register Group. Subcutaneous fat necrosis in neonates with hypoxic ischaemic encephalopathy registered in the Swiss National Asphyxia and Cooling Register. BMC Pediatr. 2015 Jul 9 15:73.

9. Muzy G, Mayor SAS, Lellis RF. Subcutaneous fat necrosis of the newborn: clinical and histopathological correlation. An Bras Dermatol. 2018 Jun 93(3):412-414.

10. Chuang SD, Chiu HC, Chang CC. Subcutaneous fat necrosis of the newborn complicating hypothermic cardiac surgery. Br J

Dermatol. 1995 May 132(5):805-10.

11. Kellar A, Tangatco JA, Weinstein M, Saunders N. Subcutaneous

Fat Necrosis of the Newborn With Initial Hypocalcemia and Familial Recurrence: A Case Report. J Cutan Med Surg. 2018 Mar/Apr 22(2):223-225.

Southern Philippines Medical Center Journal of Health Care Services Editors

Editor in Chief: Alvin S Concha • **Associate Editors:** Christine May Perandos-Astudillo, Rodel C Roño, Melivea I Melgazo, Seurinane Sean B Española

Managing Editor: Clarence Xlasi D Ladrero • **Layout Editor:** Clarence Xlasi D Ladrero

SPMC JHCS OFFICE Research Utilization and Publication Unit, Acacia Room, Level 3 Outpatient Building, Southern Philippines Medical Center, JP Laurel Avenue, Davao City, Philippines

Landline (+6382) 2272731 loc 4127 • **Website** www.spmcjournal.com • **Email** spmcpapers@gmail.com